

## A Case of Prehospital Traumatic Arrest in a US Special Operations Soldier Care From Point of Injury to Full Recovery

Myles R. McKenzie; Ernest W. Parrish; Ethan A. Miles, MD; James C. Spradling, CRNA;  
Lanny F. Littlejohn, MD; Mark D. Quinlan; George A. Barbee, PA-C; David R. King, MD

### ABSTRACT

During an assault on an extremely remote target, a US Special Operations Soldier sustained multiple gunshot and fragmentation wounds to the thorax, resulting in a traumatic arrest and subsequent survival. His care, including care under fire, tactical field care, tactical evacuation care, and Role III, IV, and V care, is presented. The case is used to illustrate the complex dynamics of Special Operations care on the modern battlefield and the exceptional outcomes possible when evidence-based medicine is taken to the warfighter with effective, far-forward, expeditionary medical-force projection.

KEYWORDS: *bleeding; arrest; thoracotomy; war; military*

### Introduction

During an assault on an extremely remote target, a US Special Operations Soldier sustained multiple gunshot and fragmentation wounds to the thorax, resulting in a traumatic arrest and subsequent survival. The detail of his care are presented.

### Case Report

#### Prologue

Under cover of darkness, in below-freezing conditions over very rough terrain, US Special Operations Forces (SOF) assaulted an extremely remote mountainous target. One Soldier came into close contact with the enemy on the target, just outside the primary objective. During the carefully executed firefight, this Soldier sustained both fragmentation injuries from a hand grenade and multiple thoracic gunshot wounds from a rifle, and was temporarily incapacitated. Medical care was initiated within moments of injury by two Special Operations (SO) medics who were also in contact with the enemy.

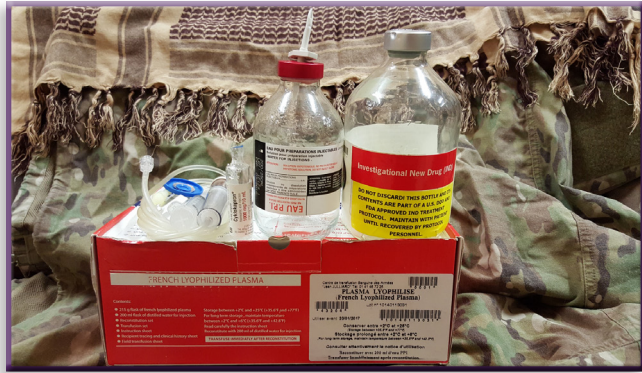
#### Care Under Fire

As the multilateral firefight continued to escalate, both SO medics responded and suppressive fire was returned. The casualty had no evidence of obvious massive external hemorrhage after performing a blood sweep (i.e., a maneuver whereby the medical provider rapidly runs his hands over the casualty's entire body palpating for wetness of skin or uniform caused by bleeding). The firefight continued to evolve and the casualty was moved downhill and away from the objective, where additional contact was received and suppressive fire was returned. The casualty was unstable on his feet but could ambulate, so he was assisted by both medics to a location of cover and concealment, where he was sat down and medical care continued.

#### Tactical Field Care

The casualty's tactical equipment was removed and an additional blood sweep was performed. The casualty was initially awake, alert, and able to answer questions. During the secondary survey, multiple lacerations were identified on the left side of his face, caused by fragmentation, as well as gunshot wounds to his anterior and posterior right shoulder. His facial lacerations did not present any life-threatening hemorrhage, but there was significant bleeding from his right shoulder. The wound was too high on the shoulder to control with a tourniquet, so it was exposed, packed with an advanced topical hemostatic dressing (Combat Gauze®; Z-Medica; <http://www.z-medica.com>) in both wound cavities, and wrapped with a pressure dressing. Simultaneously, a unit of freeze-dried plasma (FDP) was reconstituted (Figure 1). The FDP was handed off to a nonmedical Soldier to swirl for 6 minutes, so that it would be ready to administer by the time all wounds were identified and intravenous (IV) access was obtained. [Note: FDP is available to US Special Operations Command through a US Food and Drug Administration–approved Investigational New Drug protocol.]

**Figure 1** Freeze-dried plasma and tranexamic acid were administered to the casualty.



The casualty's chest wall was then assessed for injuries because he now reported difficulty breathing. The thorax was exposed, and while palpating his chest, gunshot wounds to his right high anterior chest, left high anterior chest, and a wound over his right scapula were discovered. Upon identifying each wound, vented chest seals were placed over each. The wound over the right scapula presented with a significant amount of bleeding, so the wound was packed with an advanced topical hemostatic dressing before a vented chest seal was placed over it.

Based on the clinical impression of evolving shortness of breath and increased respiratory rate, multiple 14-gauge angiocatheters were placed through the chest wall bilaterally with rushes of air, confirming bilateral tension pneumothoraces. In total, seven angiocatheters were used to serially and repeatedly decompress the chest prior to further evacuation. With each angiocatheter puncture administered, the casualty stated he felt a great improvement in his mechanics of breathing. The casualty's position of comfort was being seated upright, so he was maintained in that position the entire time care was rendered. His initial respiratory rate was 30 breaths per minute, and improved with each needle decompression.

Approximately 5 minutes into care, the casualty became very lethargic and difficult to arouse. This represented a significant change from his initial presentation and he appeared on the verge of losing consciousness. His radial pulse was absent, and only a carotid pulse could be appreciated. He had cool and clammy skin. An 18-gauge saline lock was obtained in his left antecubital fossa. One gram of tranexamic acid was pushed with a 5mL syringe over 2 minutes. The FDP was then ready to administer, but an equipment malfunction occurred such that the filtered line in the kit would not effectively draw the FDP from the glass vial. A solution was field-improvised, and a 60mL syringe with a filter needle was used to draw and slow push the FDP from the vial into the casualty. Once the FDP was administered, his mental

status was significantly improved and return of radial pulse was noted.

The casualty was placed on a litter with a hypothermia prevention and management kit consisting of a Mylar foil hypothermia blanket with chemical warming packs. A short but difficult movement ensued, with continual casualty reassessments. Due to difficulties with the litter on the terrain, the casualty ambulated himself the last 100m of this difficult movement over very rocky ground.

### Tactical Evacuation Care

At the conclusion of the movement, the casualty was reevaluated by additional medical personnel. He was displaying signs of shock but was hyperalert and complaining of shortness of breath, which worsened when he was in the supine position. He remained sitting upright while further evaluation was performed. All previously identified wounds were reevaluated. A small, portable pulse oximeter was demonstrating a heart rate of 130 beats per minute (bpm) and an oxygen saturation of 85%. Palpation of the radial artery revealed a thready pulse. The respiratory rate was 30 breaths per minute and his skin was cool and clammy. His IV access was lost during initial casualty movement and a second attempt at placement failed. A sternal intraosseous needle was successfully placed. Packed red blood cells (PRBCs), under manual pressure, were infused in line through a portable fluid warmer. The bilateral pleural spaces were decompressed again with 14-gauge angiocatheters, resulting in subjective improvement of dyspnea, although his oxygen saturation continued to deteriorate to 70%. Diagnostic ultrasonography was performed, which revealed absence of free fluid in the abdomen and pericardial spaces, although fluid was noted in both pleural spaces. Absence of lung sliding was noted. The patient continued to deny pain and was communicative.

The casualty quickly arrived at a tactical surgical element positioned near the target. He appeared ashen, obviously hypothermic, hypotensive, tachycardic, and tachypneic. He was intermittently communicative, followed some commands, and could move all four limbs. Total exposure resulted in identification and careful anatomic categorization of concerning penetrating wounds to (1) the manubrium just left of midline and inferior to the sternal notch, (2) the right anterior shoulder over the glenoid fossa, (3) to the posterior thorax just right of midline in the third thoracic interspace, and (4) to the left lateral thorax in the posterior axillary line at the fifth interspace.

The initial blood pressure obtained was 85/50mmHg, heart rate was 135 bpm, and respiratory rate was 40 breaths per minute. During casualty movements, all IV access was lost and the previously placed intraosseous

needle was found to be nonfunctional. Central venous access was immediately obtained by placing a right subclavian 8.5F introducer sheath. The patient received a combination of IV fentanyl, ketamine, and midazolam for pain management and anxiolysis. An infusion of thawed plasma and PRBCs was simultaneously started via introducer sheath through a portable fluid warmer.

Repeated focused abdominal sonography for trauma revealed no pericardial fluid, although the examination was technically limited by artifact. Lung sliding was unable to be appreciated bilaterally. The abdominal portion of the examination was unremarkable. Under local anesthesia, a right-sided tube thoracostomy was placed with a rush of air, relief of a right tension pneumothorax, and 400mL of bloody output. The casualty's hemodynamics remained poor. A left-sided tube thoracostomy was placed under local anesthesia with a rush of air and 2L of bloody output. His hemodynamics did not improve and the team postured for surgical exploration of the left hemithorax. Preparations were made for immediate surgical access to the left thorax because cardiopulmonary arrest was anticipated with induction of anesthesia.

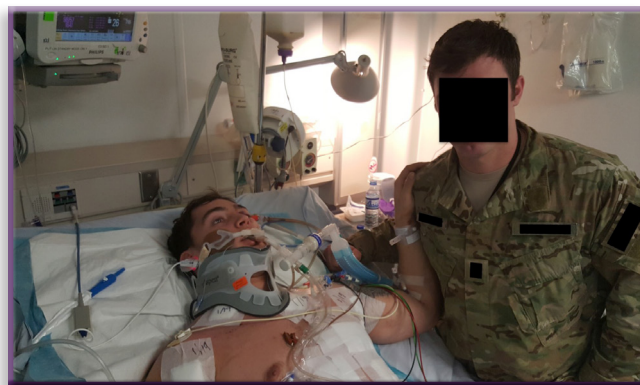Fentanyl, ketamine, midazolam, and succinylcholine were administered to facilitate a rapid sequence induction and subsequent successful endotracheal intubation. During induction, the casualty arrested and a left anterolateral thoracotomy was performed. Because of darkness and the below-freezing conditions, surgical visualization was difficult as a result of sudden condensation of the cold air entering the surgical field. A massive hemothorax containing clot and blood was evacuated from the pleural space. A pericardiotomy was performed and an empty, but uninjured, heart was delivered. A gunshot wound to the proximal pulmonary parenchyma was identified and hemostasis was temporarily obtained with a finger and transitioned to a pair of vascular clamps. The casualty's heart was massaged, blood products were administered, and, with some mechanical manipulation, the heart resumed organized electrical activity with return of spontaneous circulation. The total cardiopulmonary arrest time was approximately 7 minutes. The pulmonary vascular injury was carefully repaired with suture and clamps removed. The blood pressure was 125/88mmHg after an additional unit of plasma and PRBCs. A temporary chest closure was placed.

Subsequently, the casualty's left chest was re-explored and venous bleeding from the posterior chest wall injury was controlled with packing. The temporary chest closure was reapplied. The casualty underwent an additional long movement by fixed-wing aircraft and arrived at a Role III facility.

### Role III Care

The casualty remained hemodynamically stable through his arrival at Role III. He underwent chest washout, definitive chest closure, and a negative exploratory laparotomy done for suspicion of hollow viscus injury (Figure 2). He was awarded his Purple Heart while intubated in the intensive care unit. He was transferred, intubated, by a Critical Care Air Transport Team to a Role IV facility.

**Figure 2** The casualty, still intubated, meets one of his Special Operations medics at Role III (photo used with permission of the casualty. Names have been withheld and the photo redacted for operational security).



### Role IV/V Care

Upon arrival, the casualty was re-evaluated and transported to the operating room for washout of his wounds. He was extubated and transferred to care within the United States. After a brief hospital stay and intensive physical therapy at a rehabilitation unit, he was released home in good condition.

### Epilogue

This case represents a success of translation of evidenced-based medicine to the far-forward tactical environment. This casualty received early FDP, early pharmacologic antifibrinolysis, high-ratio transfusions, and early, far-forward expeditionary damage-control surgery. It is also notable that this casualty did not receive any crystalloid therapy during his initial several hours of care. This represents excellent execution of tactical damage-control resuscitation and surgery as a result of exceptional training of tactical military medical personnel (Table 1).

The global projection of US Military power remains a requirement in these uncertain times. Force projection of medical capabilities is an additional challenge in remote military operations and is necessary to salvage Operators from life-threatening combat wounds. This case represents successful execution of an aggressive, tactically forward, military medical posture.

**Table 1** Summary of Evidenced-Based Medicine Adapted to the Tactical Environment

Maneuver	Purpose	Outcome
Blood sweep	Rapid identification of significant extracavitary hemorrhage	Successful identification of multiple bleeding wounds
Hemostatic dressing	To provide improved hemostasis over standard gauze dressing	Cessation of bleeding from all wounds treated with hemostatic dressings
Freeze-dried plasma	Far-forward prevention and treatment of trauma-related coagulopathy, volume expansion	Improved intrinsic coagulation, improved hemodynamics
Tranexamic acid	Antifibrinolysis for early treatment and prevention of trauma-related hyperfibrinolysis	Early treatment of hyperfibrinolytic state, improved intrinsic coagulation, improved hemodynamics
Needle decompression	Relief of tension pneumothorax	Repeated successful treatment of recurrent tension pneumothoraces
Hypothermia prevention and management kit	Prevention and treatment of hypothermia	Mitigation of hypothermia in tactical, below-freezing conditions
Portable ultrasonography	Diagnostic test for internal hemorrhage	Intracavitary bleeding identified within bilateral pleural spaces, exclusion of intra-abdominal hemorrhage
High-ratio transfusion with warmed blood products	Prevention and treatment of trauma-related coagulopathy, volume expansion without hemodilution (damage control resuscitation)	Restoration of hemodynamics after hemorrhage control
Tactical surgery	Far-forward, expeditionary, abbreviated surgical hemostasis (damage control surgery)	Definitive hemorrhage control of internal bleeding within moments of injury
Training	To train as we fight, enhance complex tactical decision-making, adoption of evidence-based medicine to the tactical environment	Medical-force projection into the tactical environment
Avoidance of crystalloid	To prevent acidosis and hemodilution, prevention of coagulopathy	No crystalloids were administered, avoiding hemodilution and coagulopathy

**Disclosures**

The authors have nothing to disclose.

**LTCDR Spradling** was a member of the tactical assault force involved in the events described in this article.

**LTCDR Littlejohn** was a member of the tactical assault force involved in the events described in this article.

**SGT McKenzie** was a member of the tactical assault force involved in the events described in this article.

**Ssg Quinlan** was a member of the tactical assault force involved in the events described in this article.

**SGT Parrish** was a member of the tactical assault force involved in the events described in this article.

**MAJ Barbee** was a member of the tactical assault force involved in the events described in this article.

**LTC Miles** was a member of the tactical assault force involved in the events described in this article.

**LTC King** was a member of the tactical assault force involved in the events described in this article. He is an attending trauma and acute care surgeon. E-mail: dking3@mg.harvard.edu.